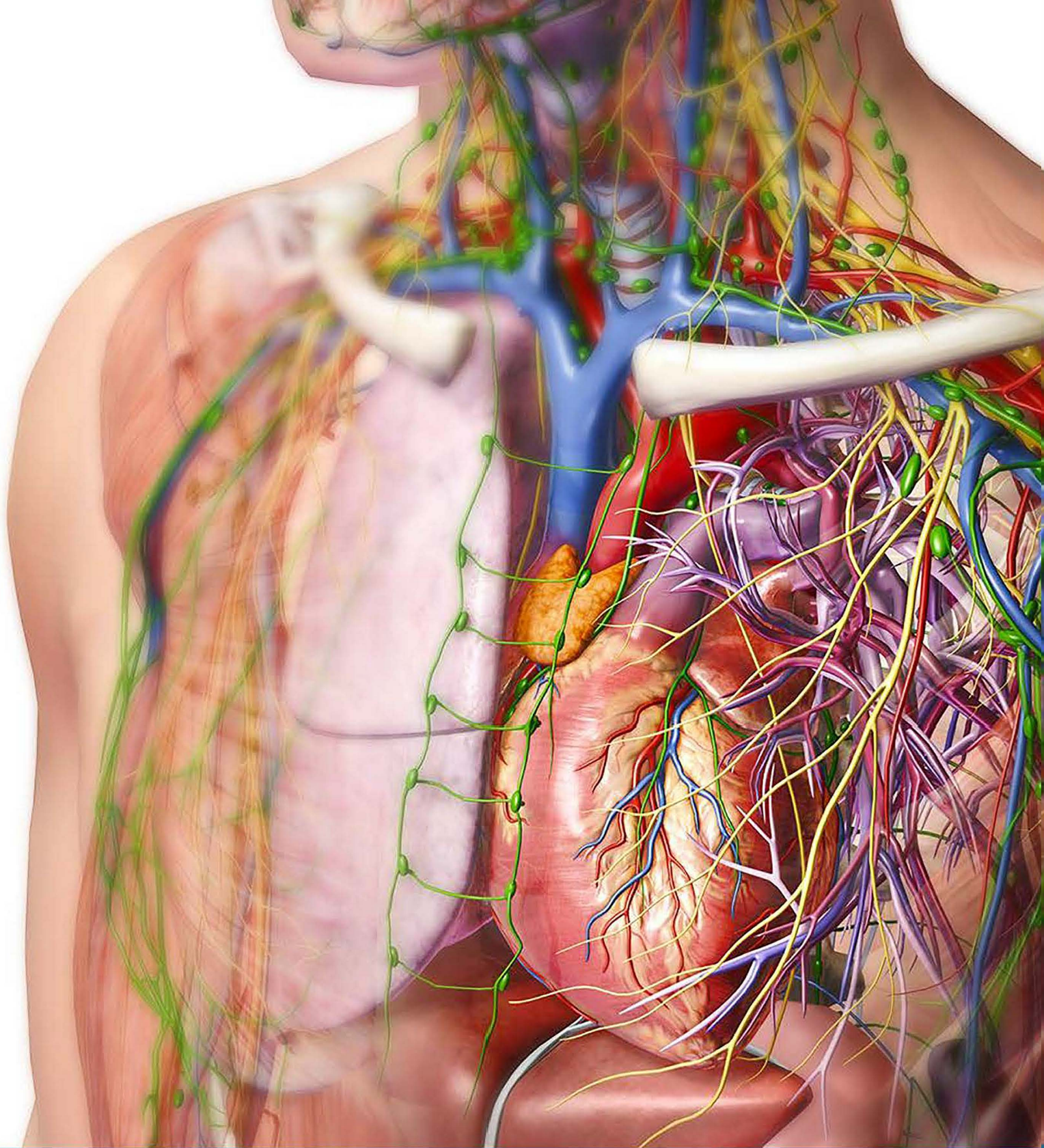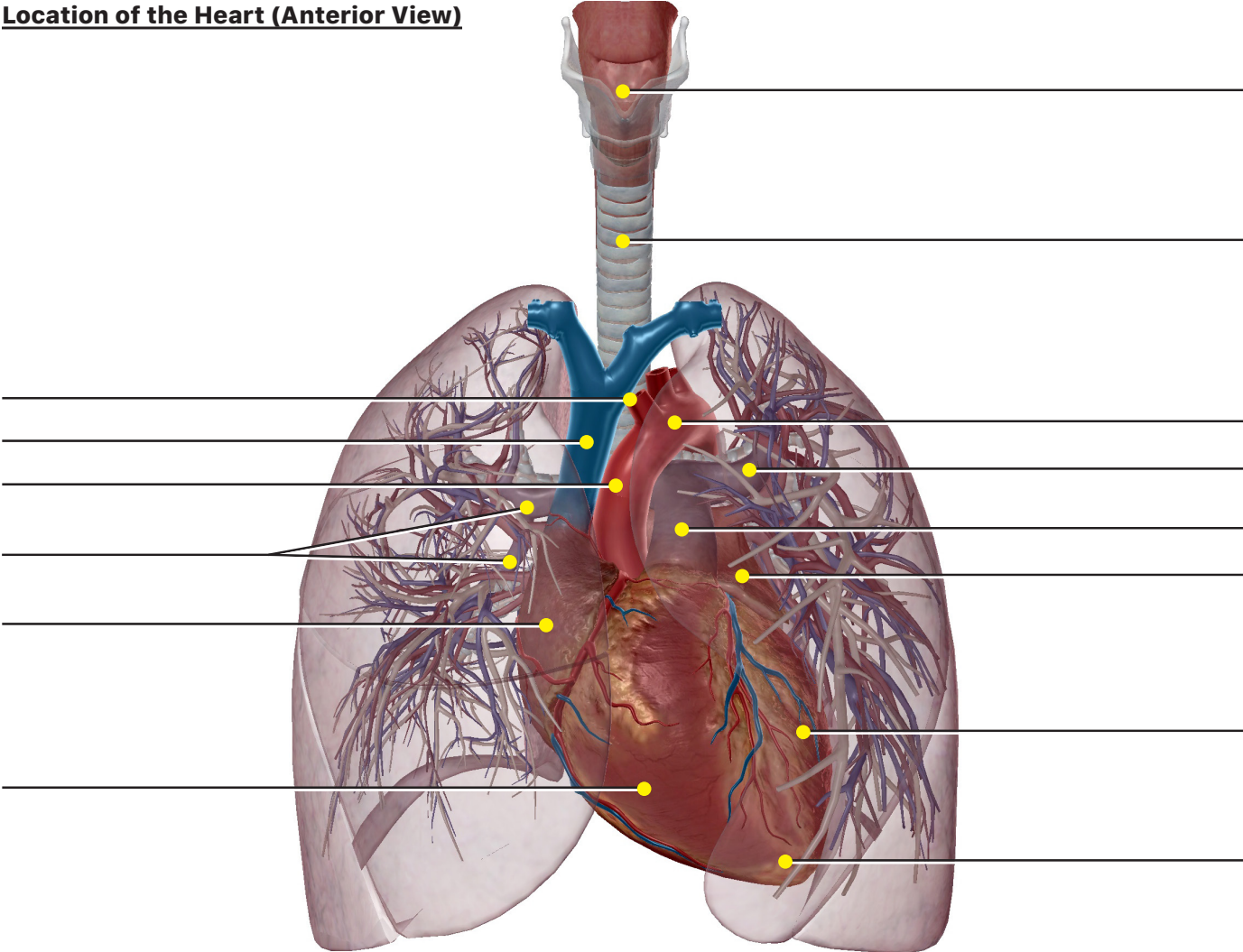


VISIBLE  BODY®

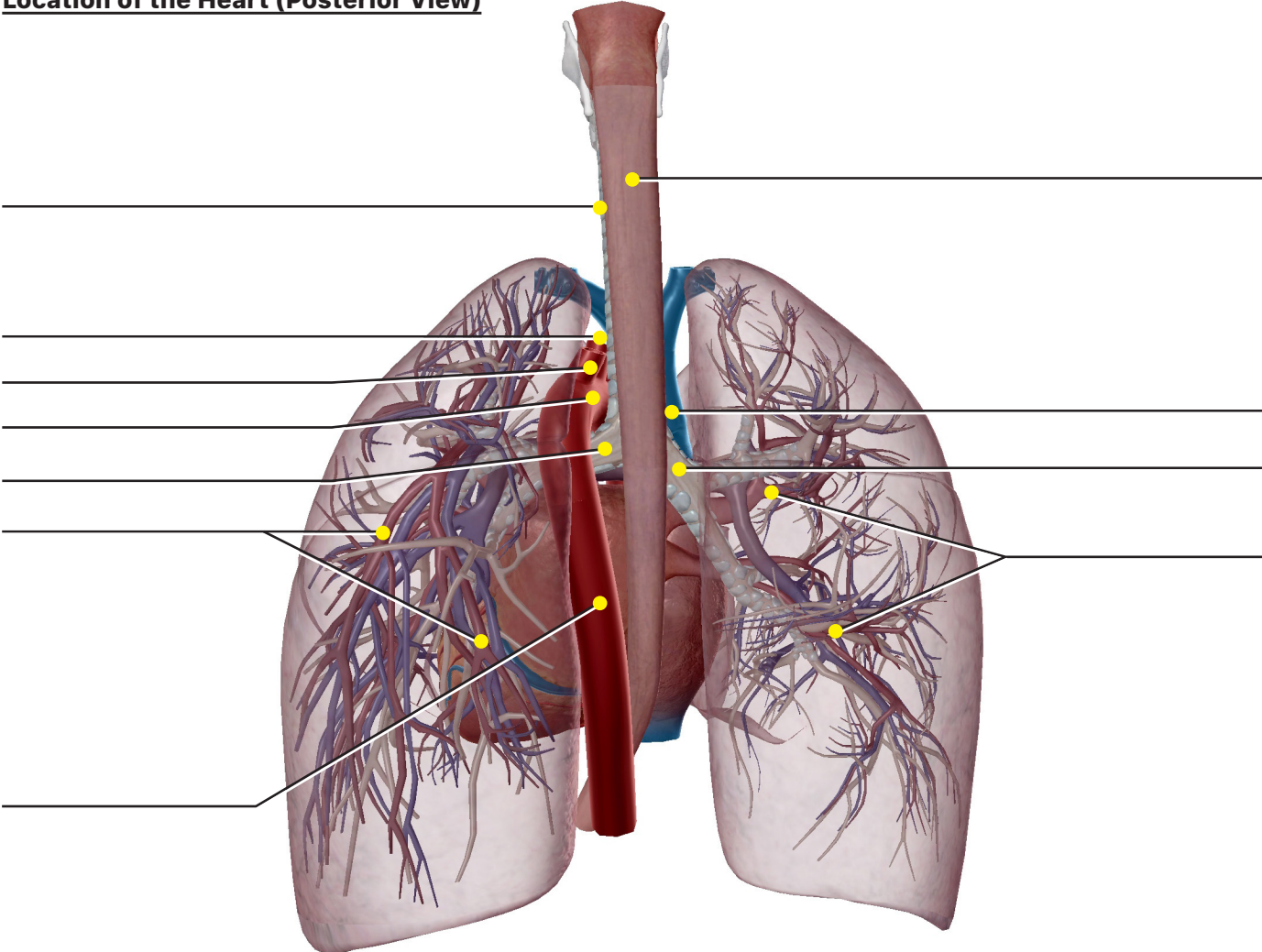
Student Practice

Label the structures in the following figures.

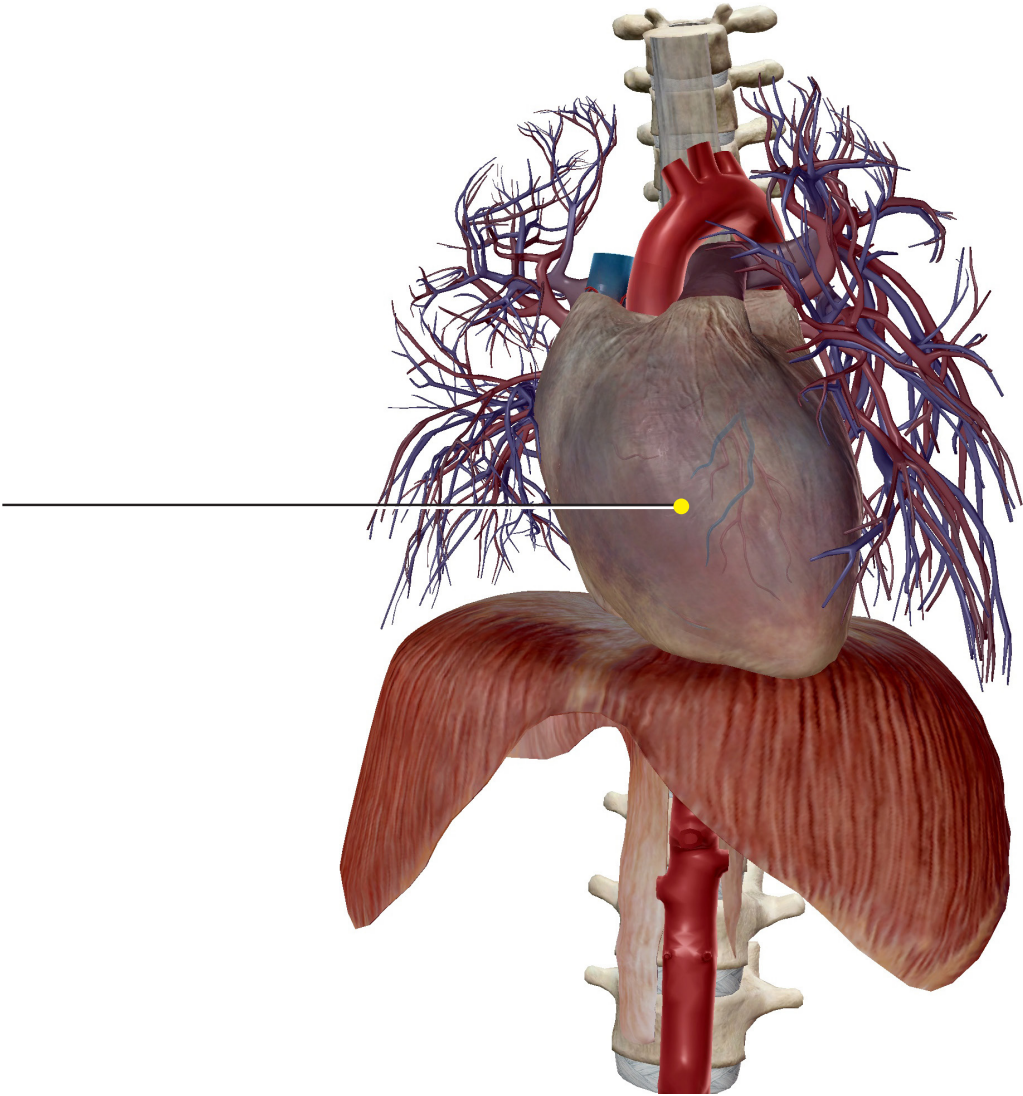
Location of the Heart (Anterior View)



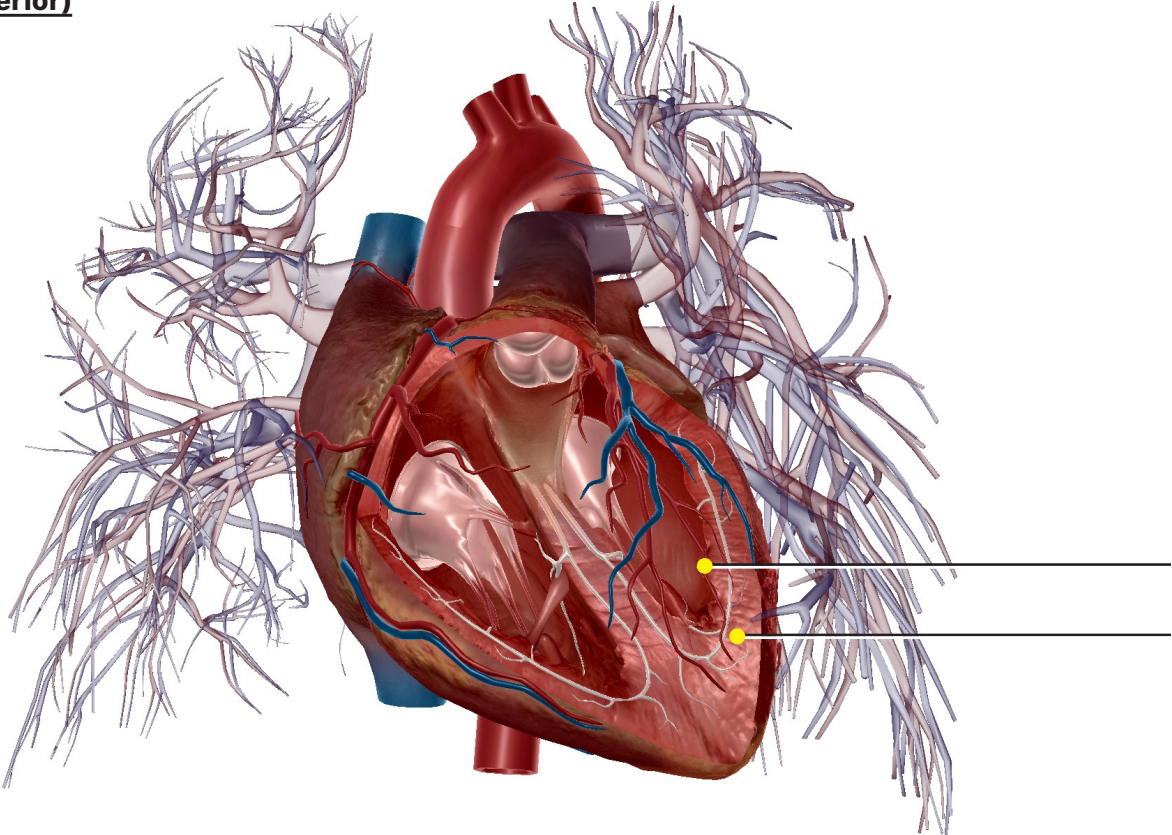
Location of the Heart (Posterior View)



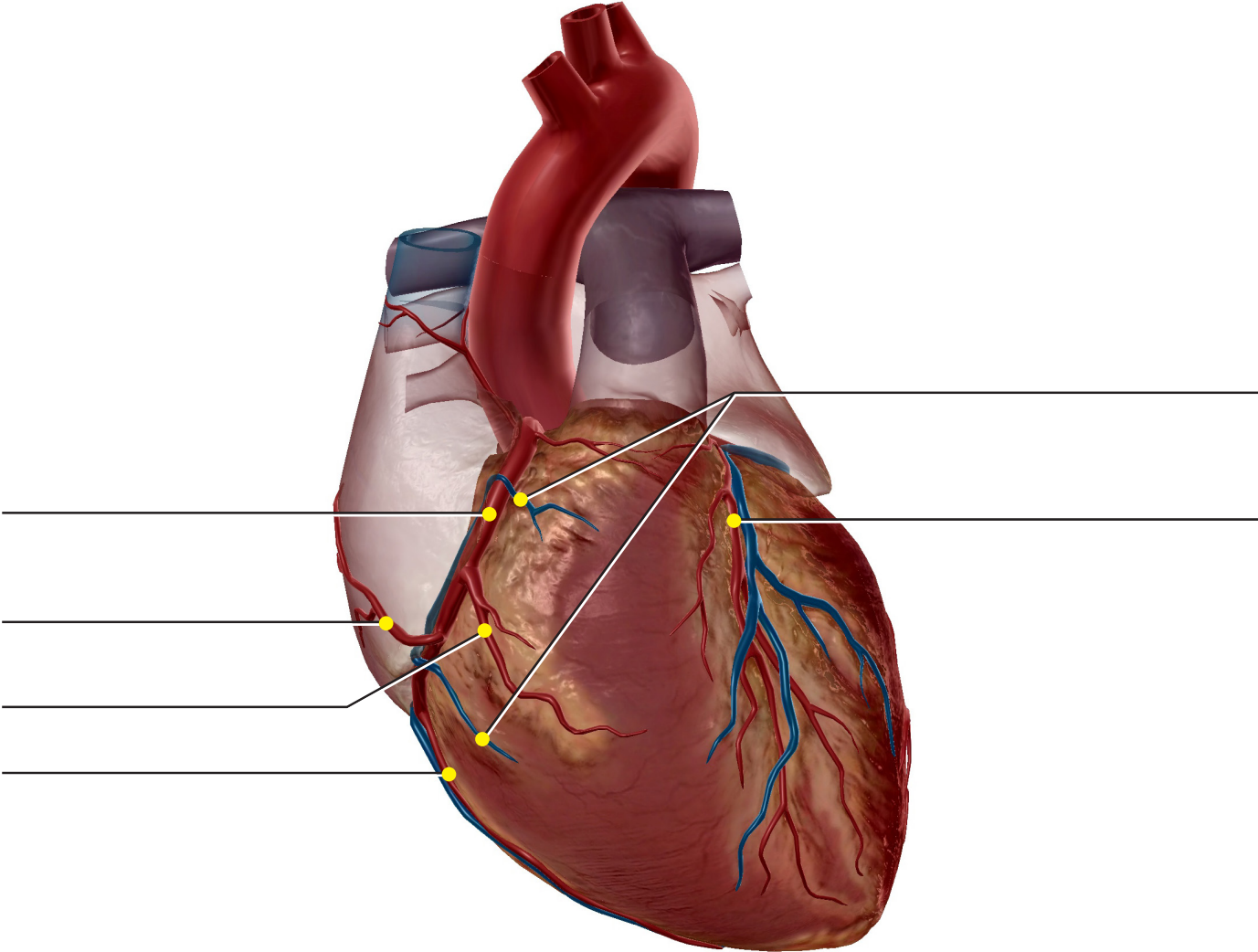
Heart Wall (Exterior)



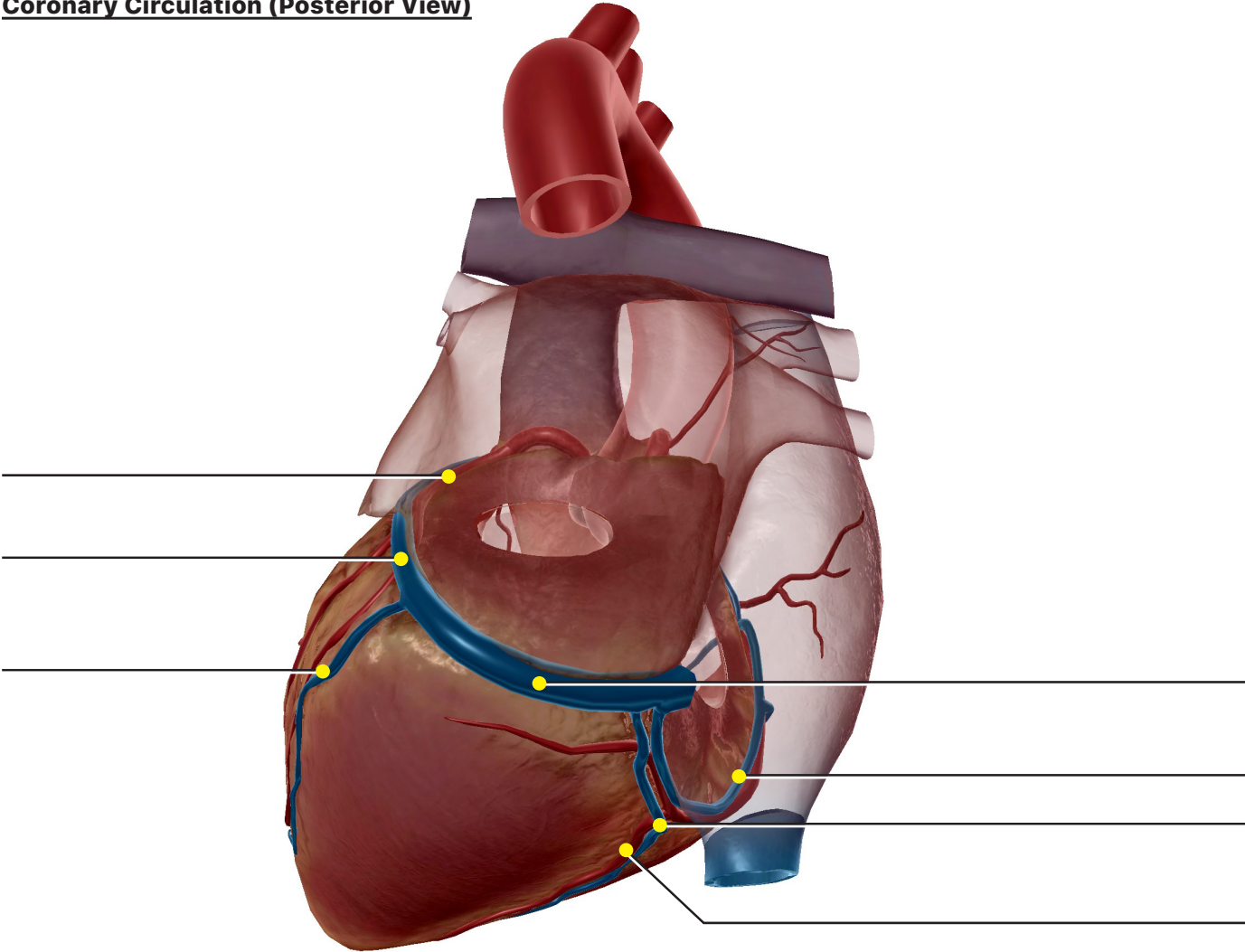
Heart Wall (Interior)



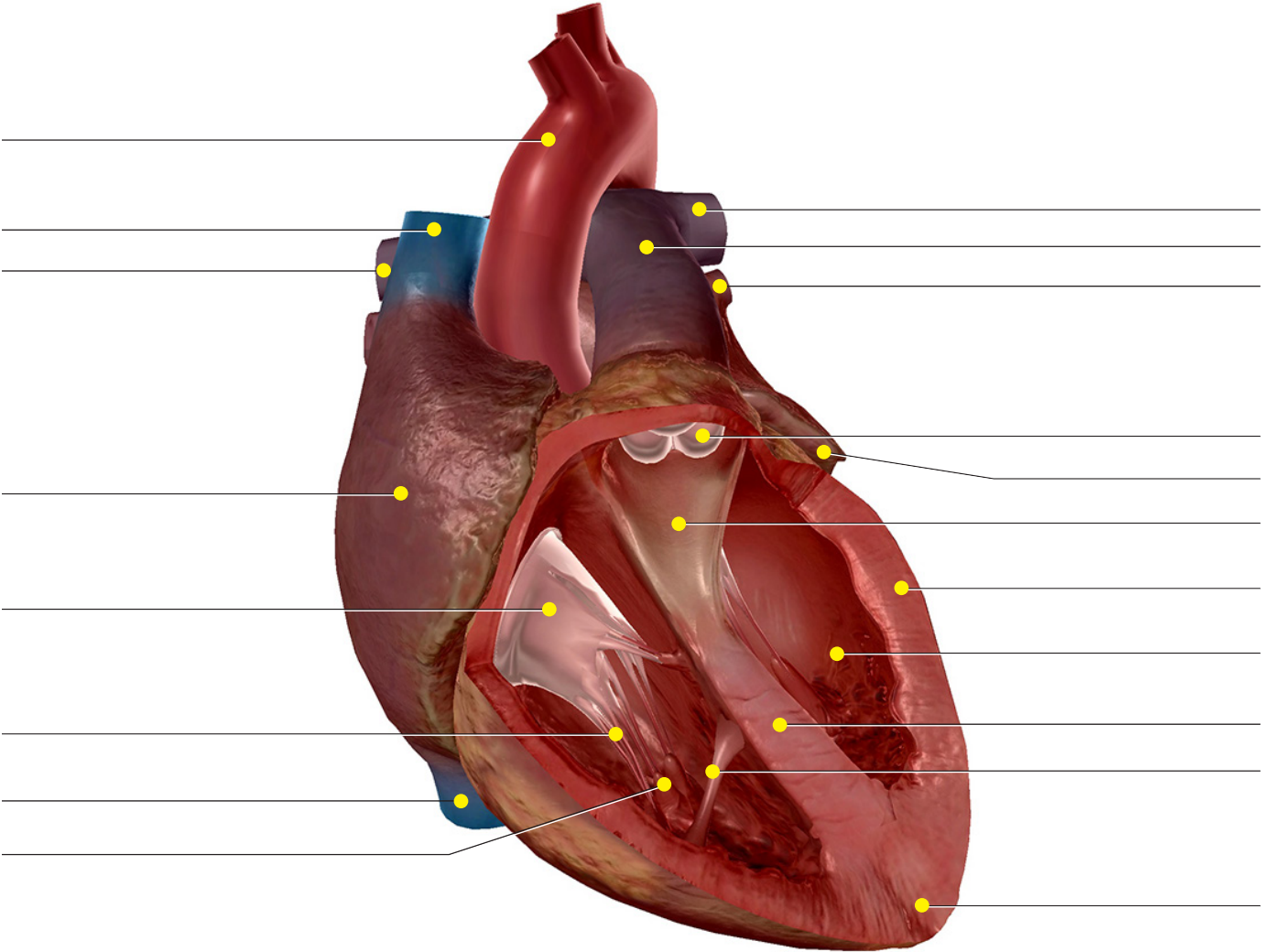
Coronary Circulation (Anterior View)



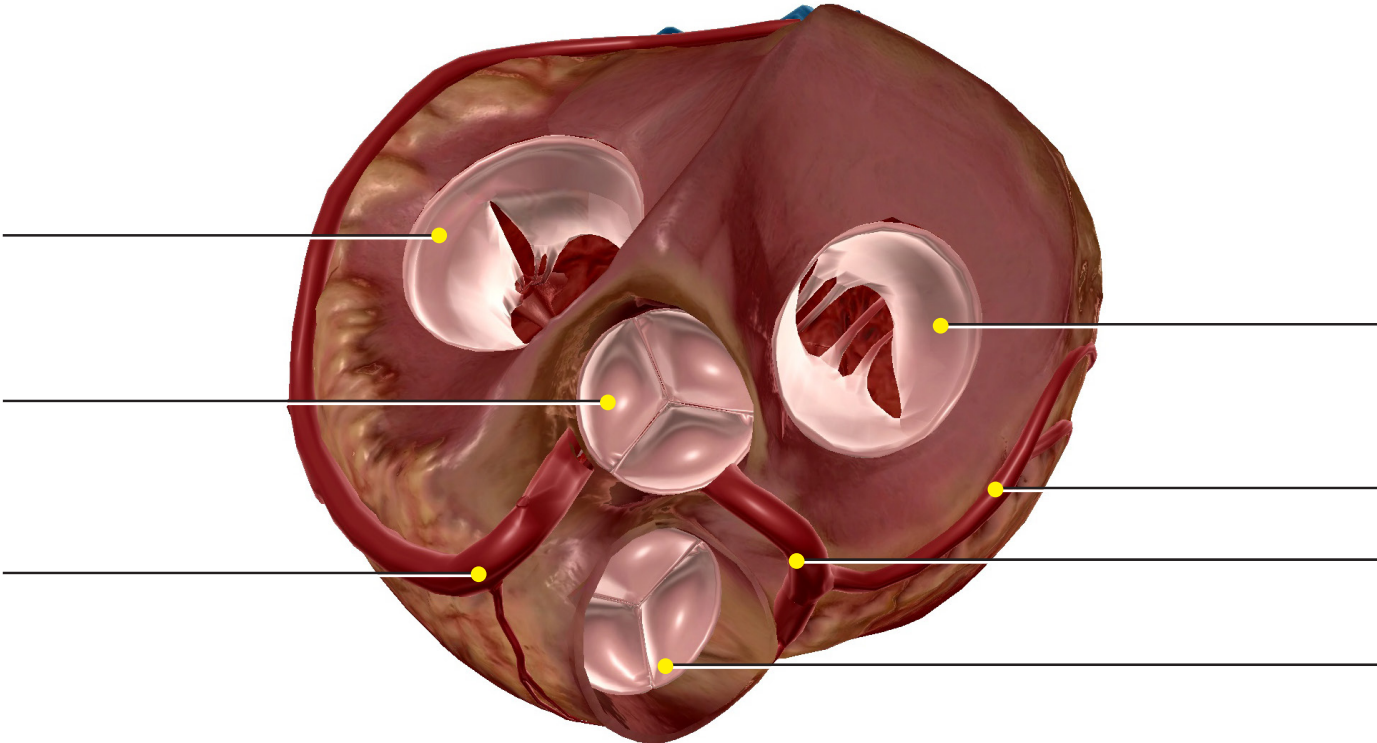
Coronary Circulation (Posterior View)



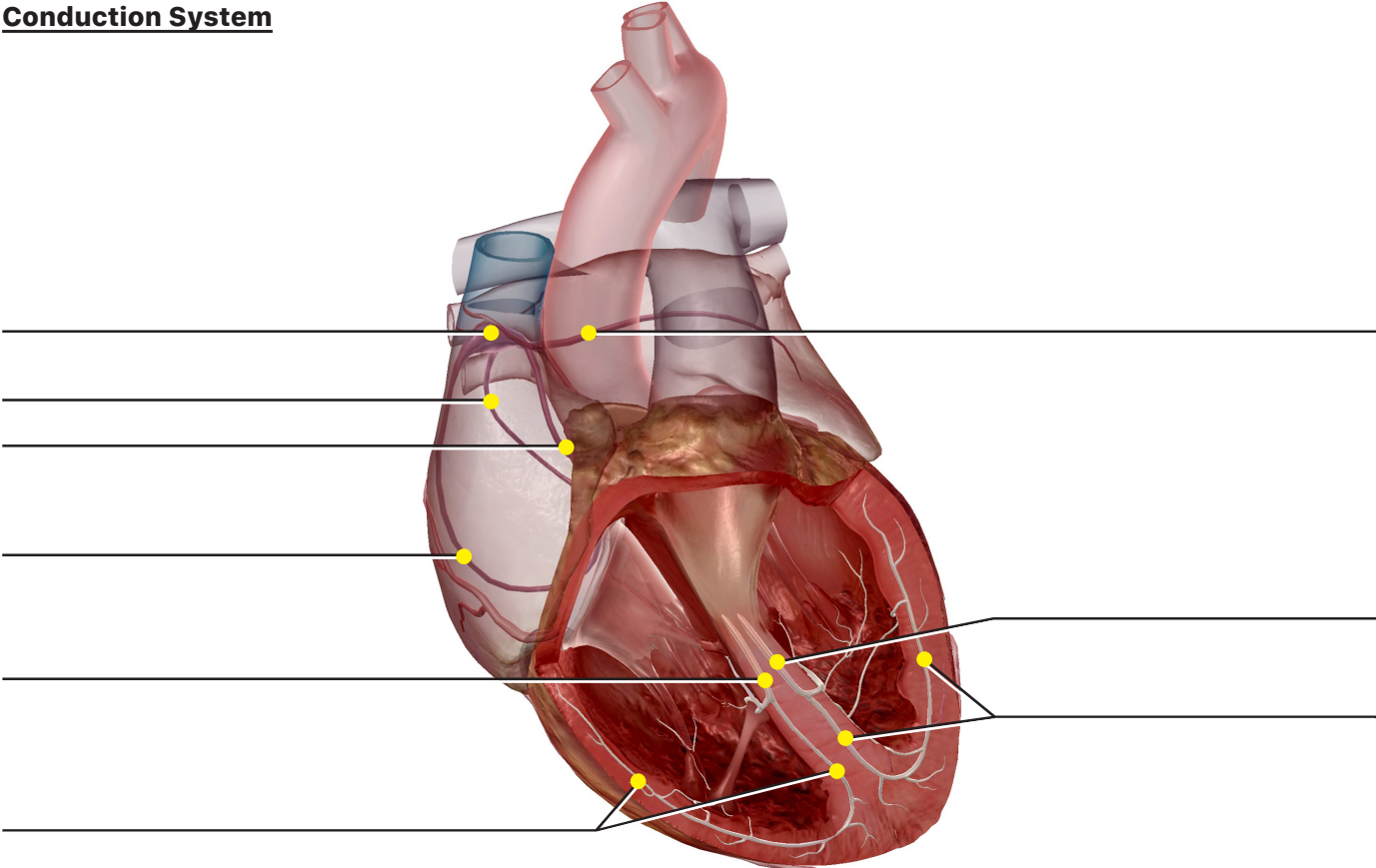
Heart Internal Anatomy



Heart Valves



Conduction System



Cross section (Inferior view)

